

## Strut Allograft Augmentation Restores Bone Stock in Revision Elbow Arthroplasty, but is not Universally Successful in Preventing a Second Revision

Daniel Z. You MD MSc<sup>1</sup>, Samuel S. Rudisill MD<sup>1</sup>, Michael Baird MD<sup>1</sup>, Shawn O' Driscoll MD PhD<sup>1</sup>, Joaquin Sanchez-Sotelo<sup>1</sup>, Mark Morrey MD MSc<sup>1</sup>

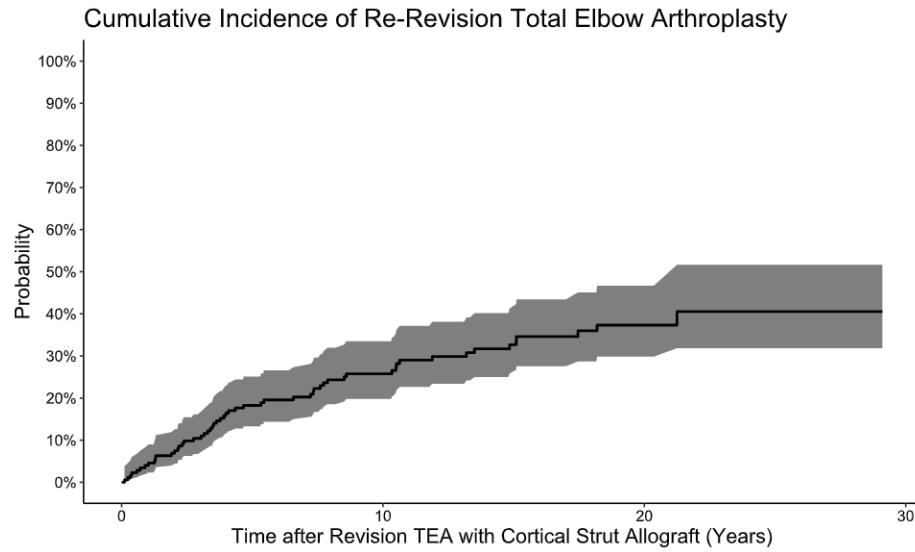
1. Department of Orthopedic Surgery, Mayo Clinic, Rochester, MN, USA

**Background.** The increased utilization of total elbow arthroplasty (TEA) in the trauma setting, coupled with younger patient age and longer population survival, is translating into an increasing revision burden. Revision TEA can be challenging as most procedures are performed without revision-specific implants, making satisfactory implant fixation difficult to achieve in the common circumstance of deficient bone stock. Strut allograft reconstruction represents an appealing option to address bone deficiency since it provides immediate structural support and the theoretical advantage of graft incorporation to restore bone stock. However, evidence supporting its efficacy is limited to small case series studies. This study aimed to determine overall strut allograft incorporation rates, complication rates, and cumulative incidence of re-revision in a large series of elbows that underwent revision TEA with strut allograft augmentation.

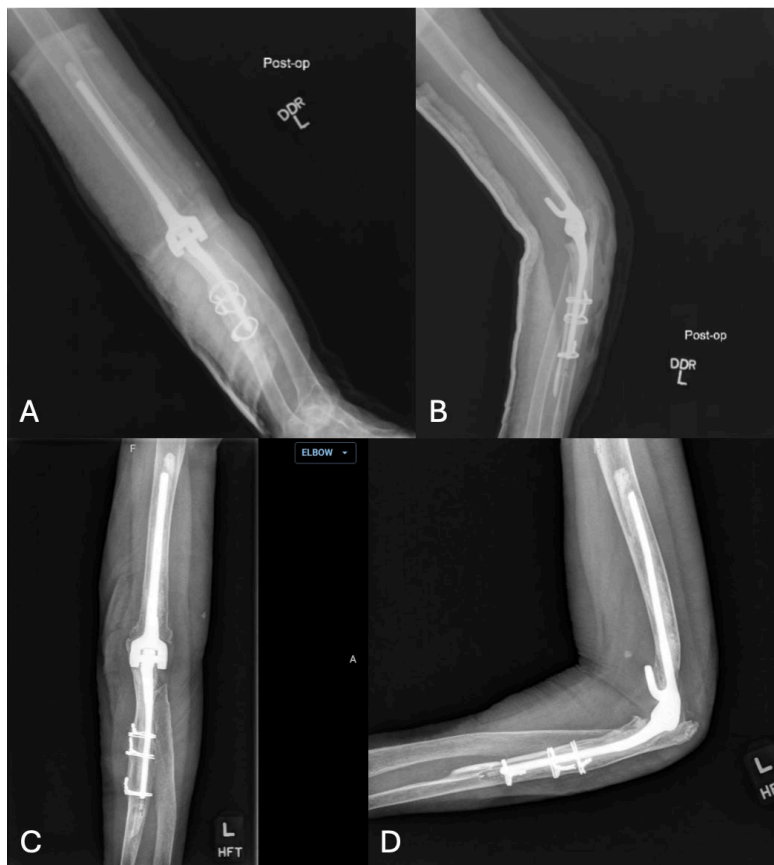**Material & Methods.** Adult patients who underwent revision TEA with strut allograft augmentation between 1990 and 2024 with minimum 2-year follow-up were identified using our institutional Total Joint Registry Database. Elbows that had undergone primary TEA with strut augmentation, revision TEA with allograft prosthetic composite reconstruction, or revision of a deficient segment of bone with a custom-made implant were excluded. There were 178 elbows followed for an average of 9 (SD 6) years. 73% were in female patients with a mean age of 61 years (standard deviation [SD] 12). Most elbows (60%) had undergone only one TEA procedure prior to the index revision TEA. Cortical strut allografts were most often used for humeral-sided reconstruction (48%), followed by ulnar-sided (38%), and both sides (13%). The most common indications for revision TEA with strut allograft reconstruction were aseptic loosening (55%), peri-prosthetic fracture (24%), and mechanical failure (10%). Two reviewers independently reviewed all medical records, operative notes, and radiographs to confirm study eligibility and record baseline demographic information, indication for revision TEA, and subsequent complications and reoperations. A senior fellowship-trained surgeon evaluated orthogonal radiographs to assess graft incorporation. Continuous variables were reported using mean (SD), and categorical variables were summarized using counts (percentage [%]). Survivorship analyses were performed to determine cumulative incidences of re-revision TEA over time accounting for death as a competing risk, with results reported as probabilities (%) with 95% confidence intervals (CI).

**Results.** Strut allograft augmentation allowed satisfactory implantation of off-the-shelf implants in all elbows. However, 55 (31%) elbows eventually underwent re-revision at a mean of 6 (SD 5) years postoperatively. Among the 121 elbows with available follow-up radiographs, 113 (93%) demonstrated graft incorporation. When adjusting for death as a competing risk, the cumulative incidences of re-revision TEA at 1, 2, 5, and 10 years were 5% (95% CI 2 – 9), 7% (95% CI 4 – 12), 18% (95% CI 13 – 24), and 24% (95% CI 19 – 32), respectively. Aseptic loosening (44%), infection (29%), and peri-prosthetic fracture (18%) were the most common indications for re-revision. Of the peri-prosthetic fractures (n=13), the majority occurred in cases where the strut and implant ended at the same level (46%) or when the strut had failed to show radiographic signs of incorporation (31%).

**Discussion.** Deficient humeral and ulnar sided bone stock can be effectively managed with strut allograft augmentation in revision TEA. Radiographic signs of graft incorporation are commonly appreciated at follow-up. The risk of periprosthetic fracture after revision TEA with strut augmentation may be related to the strut and implant ending at the same level. Despite early success of this technique for most elbows within the first two years, survivorship free of revision, accounting for death as a competing risk, approaches 75% at 10 years.



**Figure 1.** Cumulative incidence of re-revision total elbow arthroplasty after initial revision total elbow arthroplasty with strut allograft reconstruction accounting for death as a competing risk. Shaded area indicates 95% confidence interval.



**Figure 2.** Immediate post-operative (A,B) and 9-year follow-up (C,D) orthogonal radiographs demonstrating allograft strut incorporation following an ulnar sided strut allograft reconstruction for a mal-rotated ulnar component resulting in severe bushing wear and metallosis.